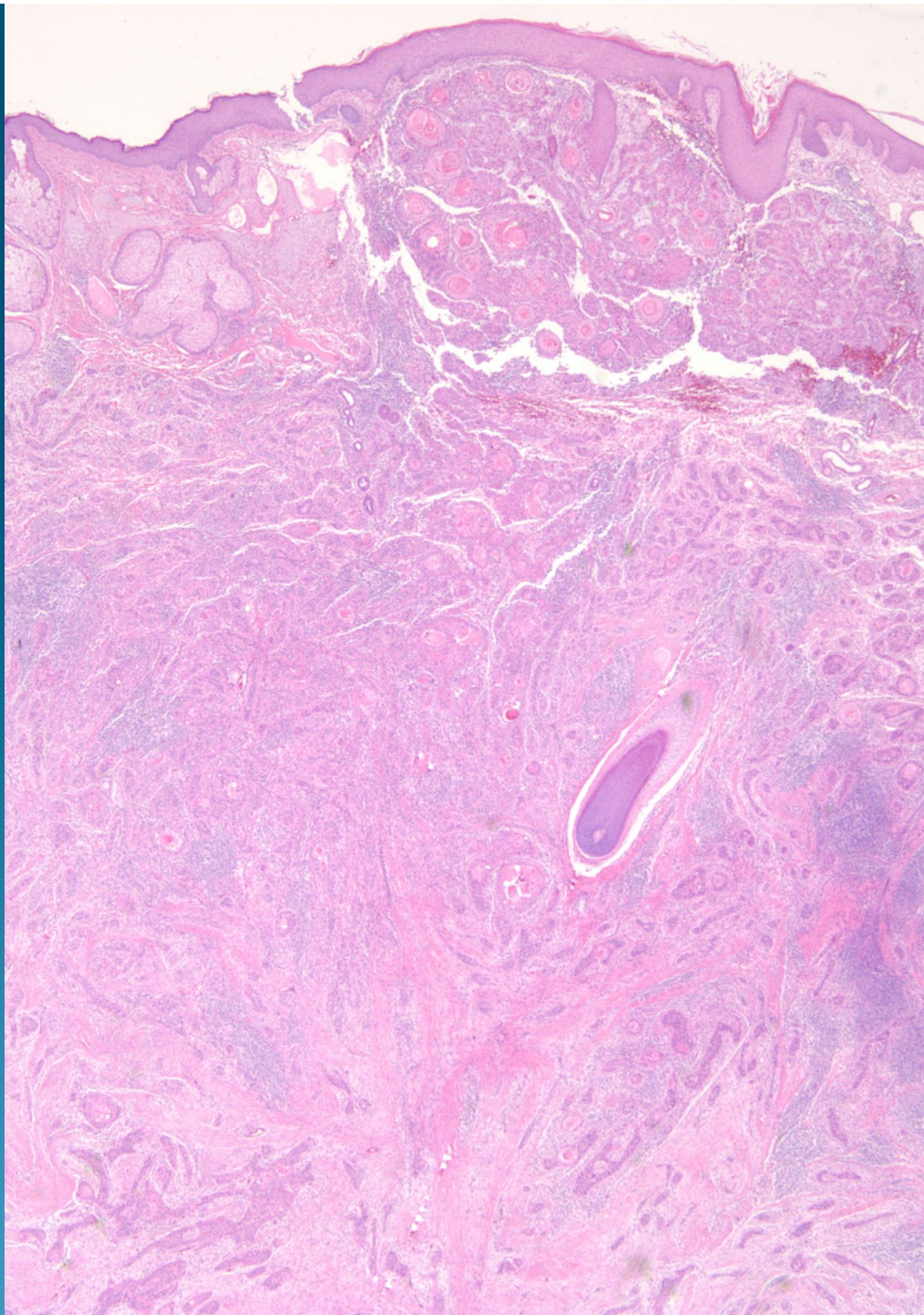
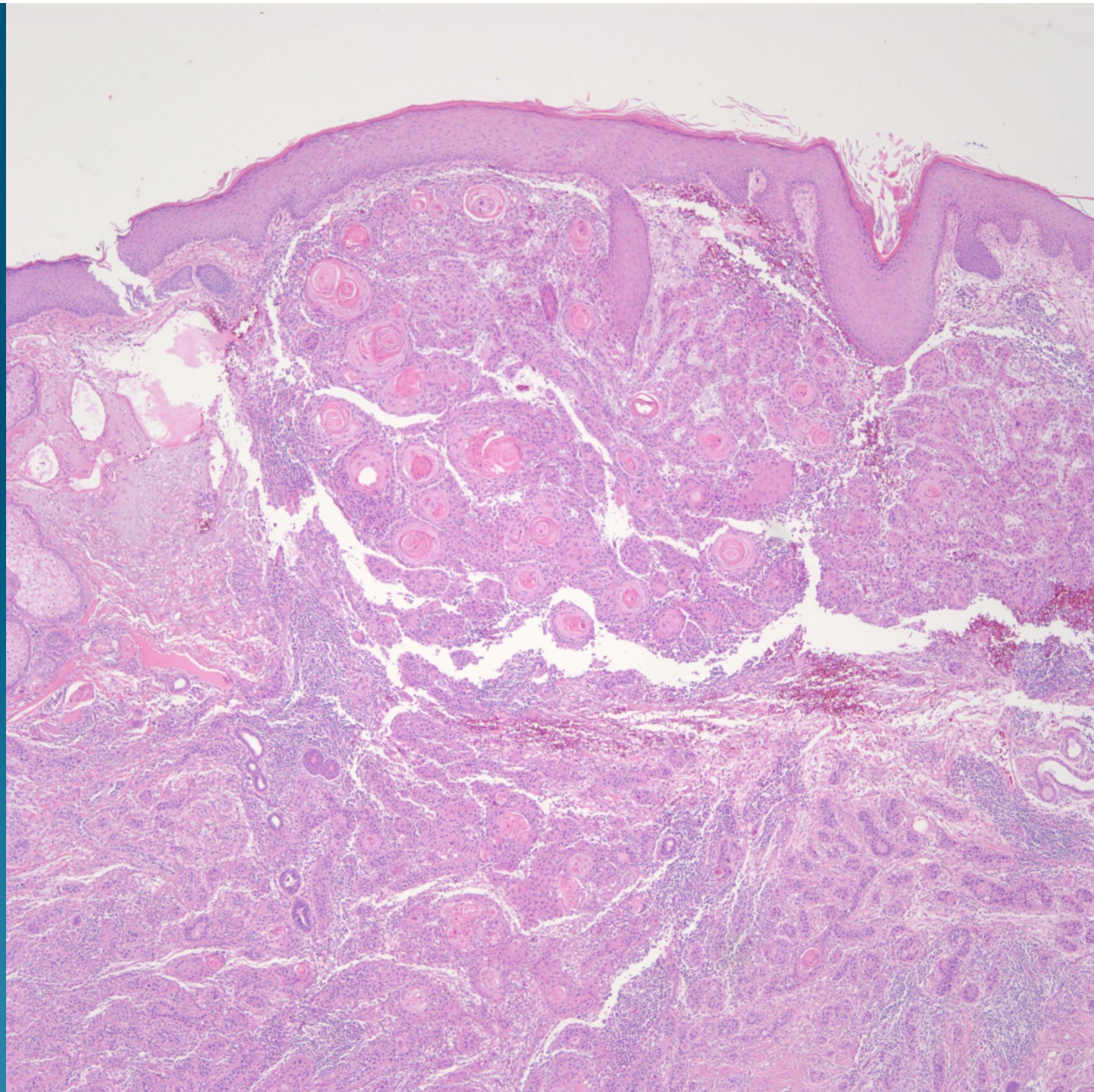
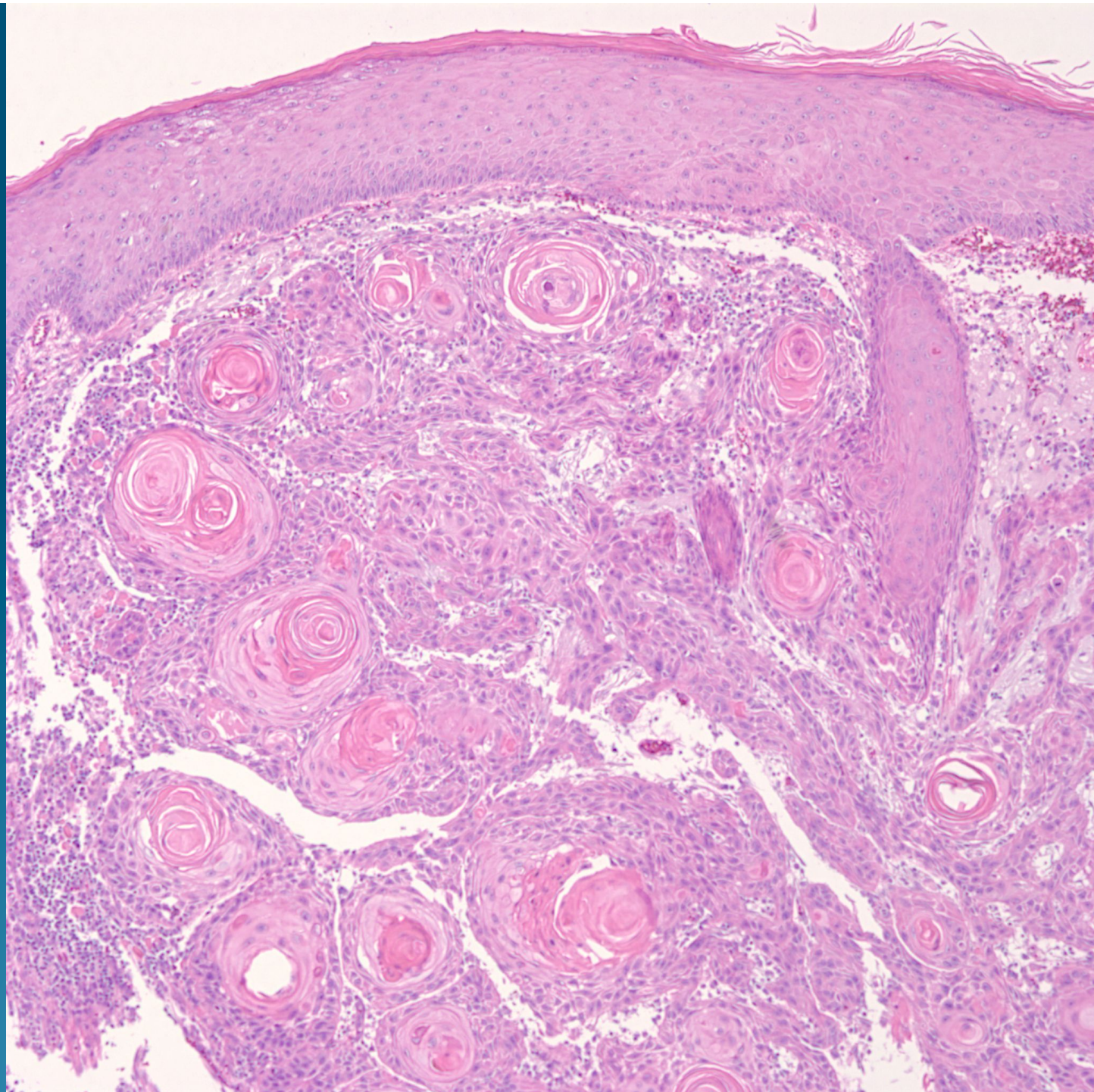

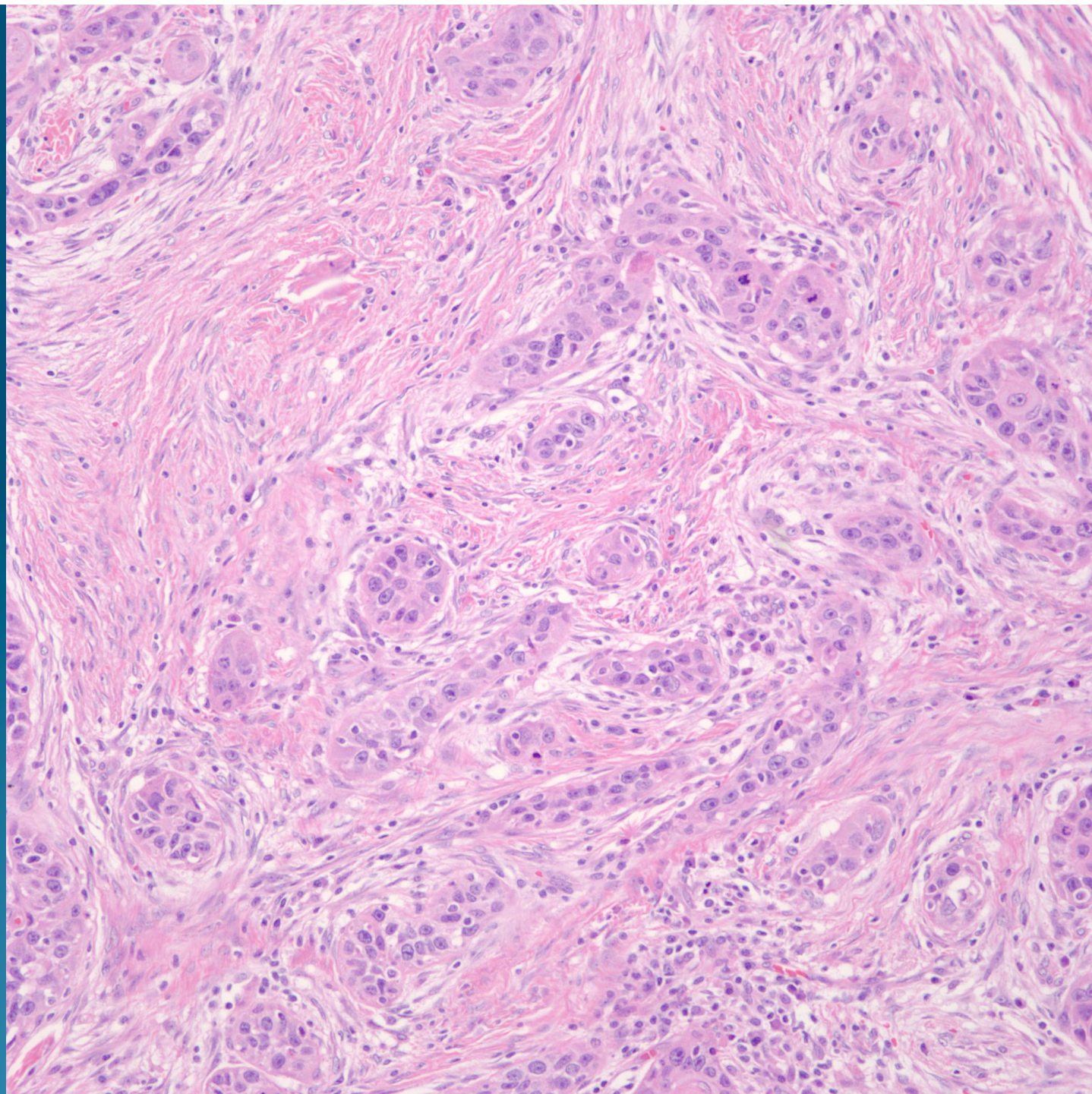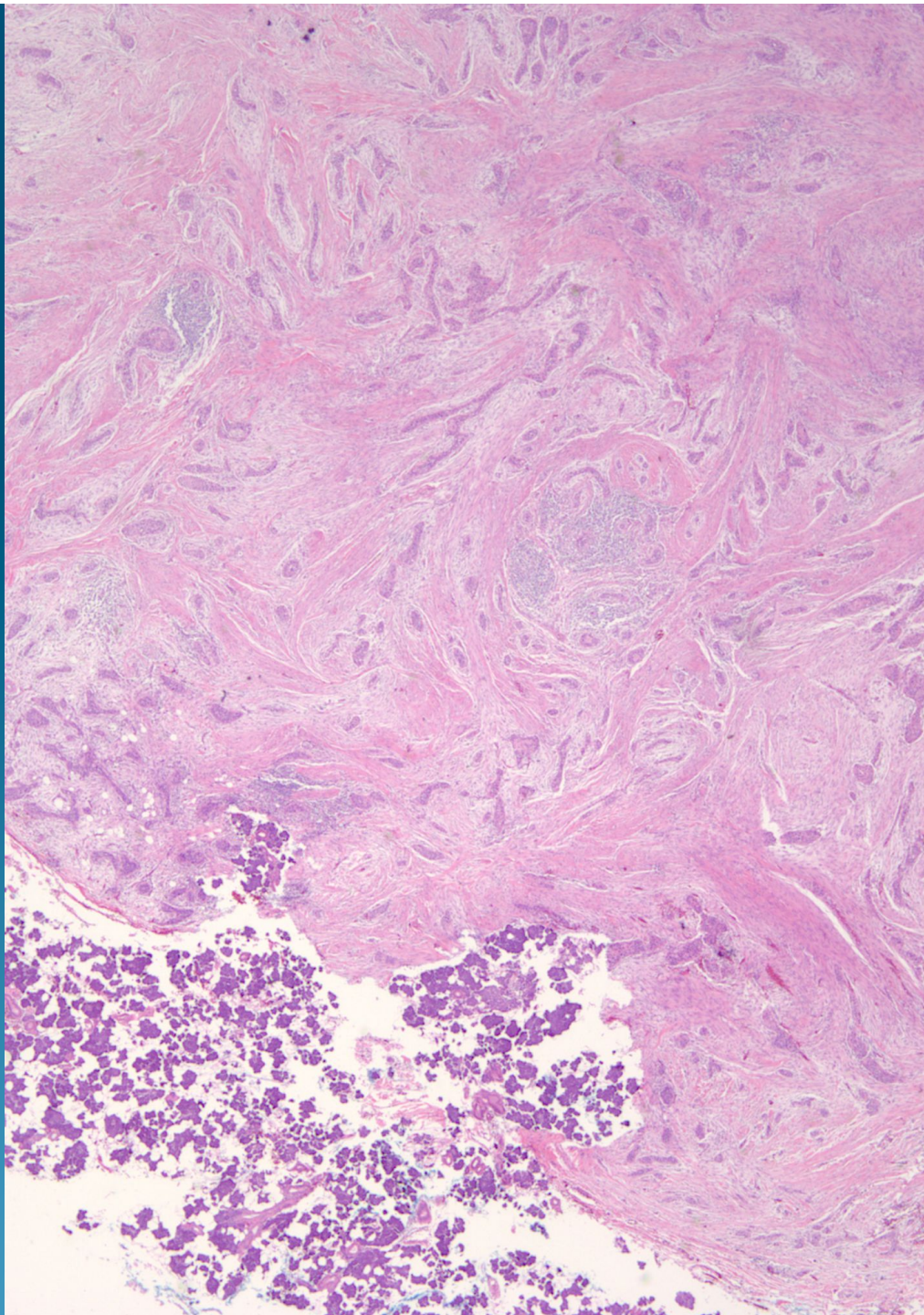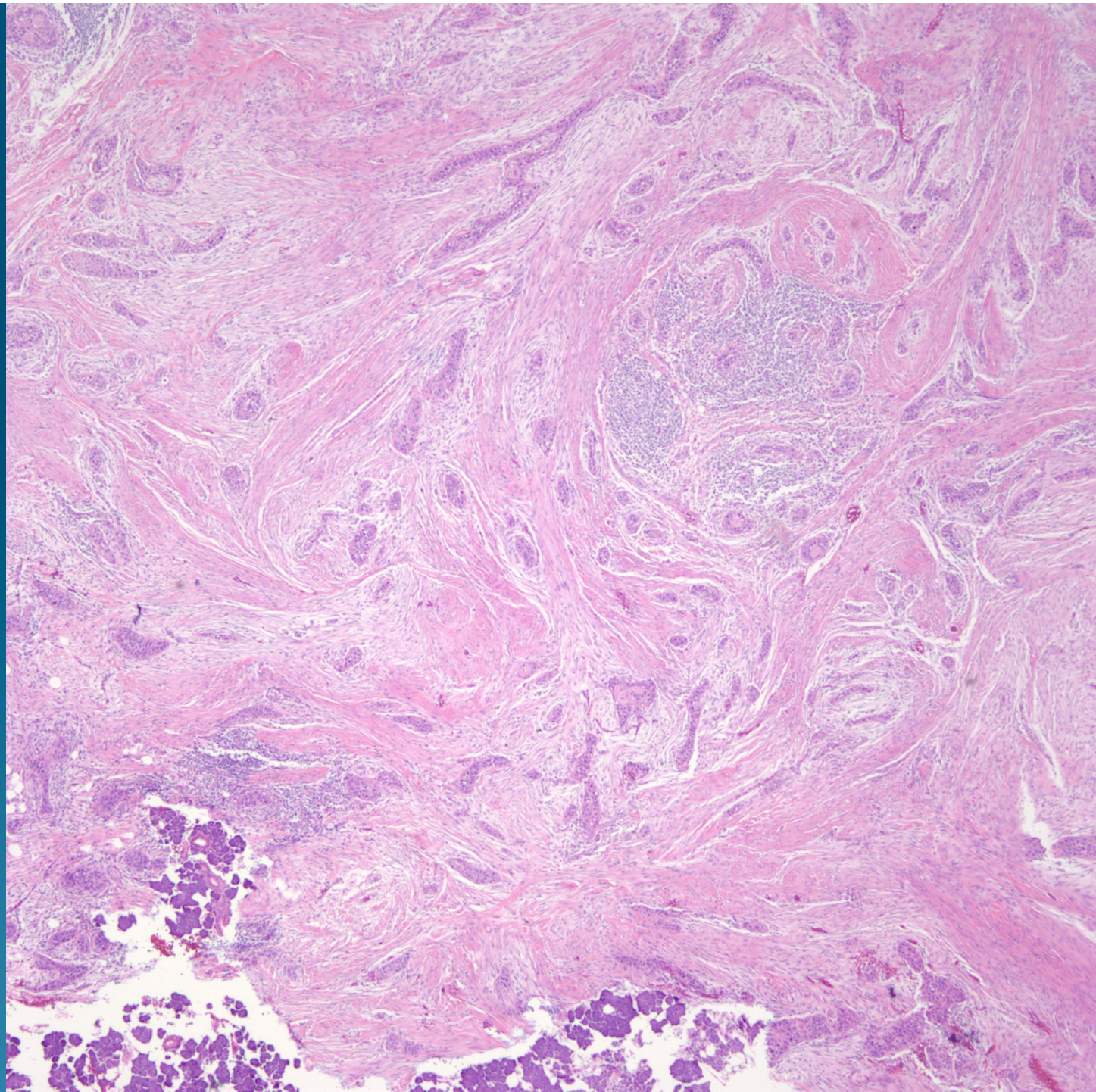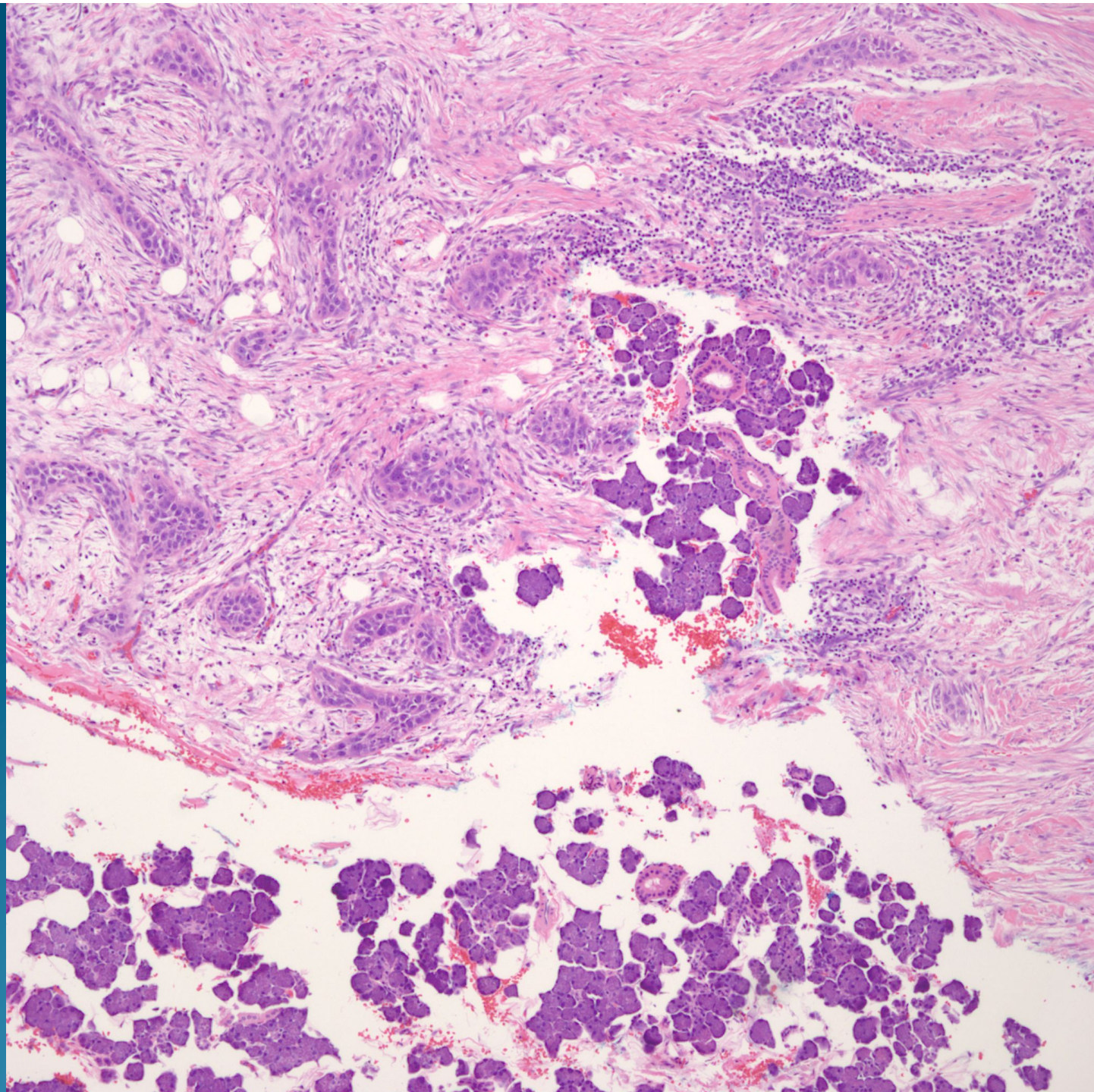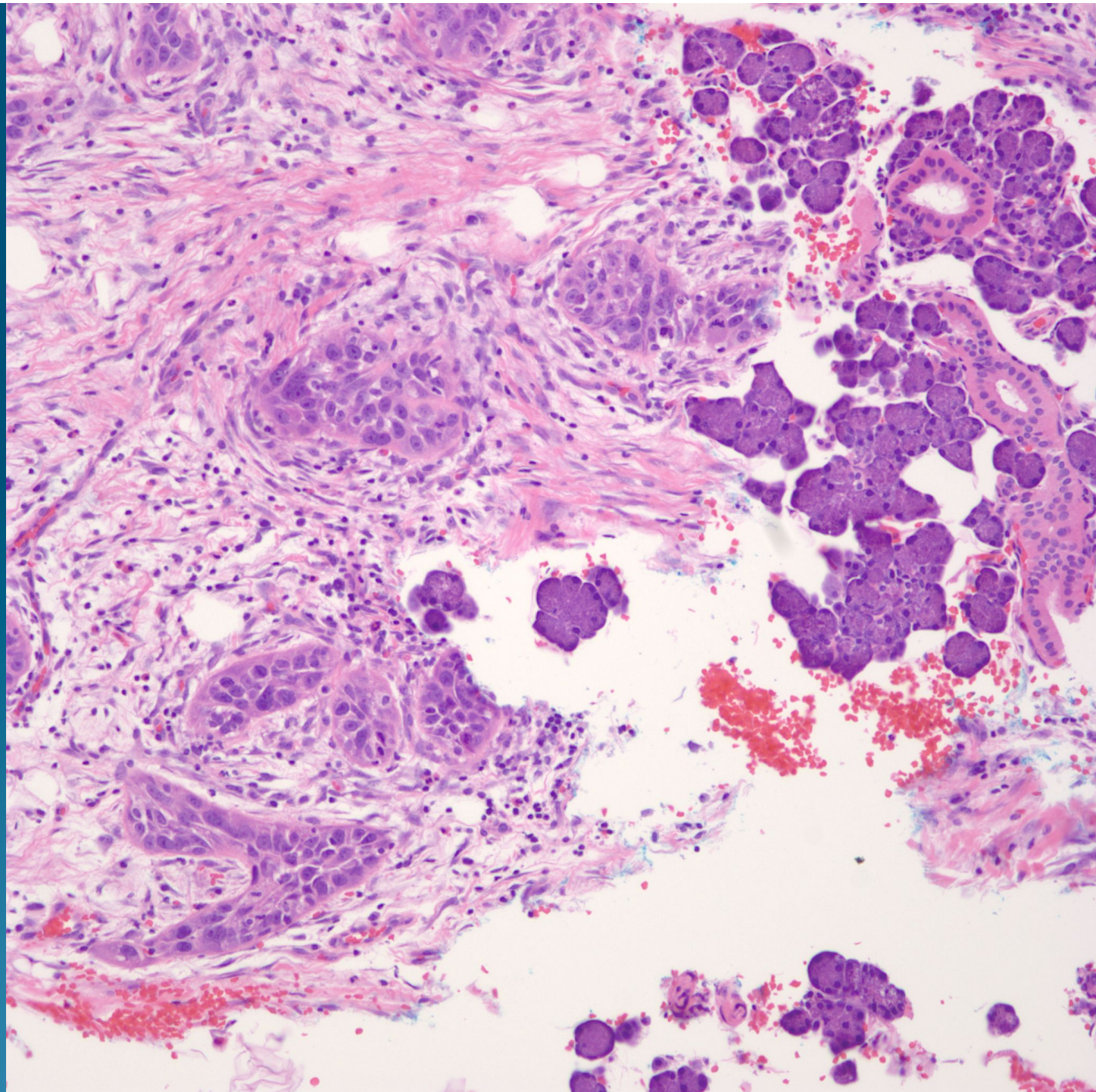# What is the best diagnosis?

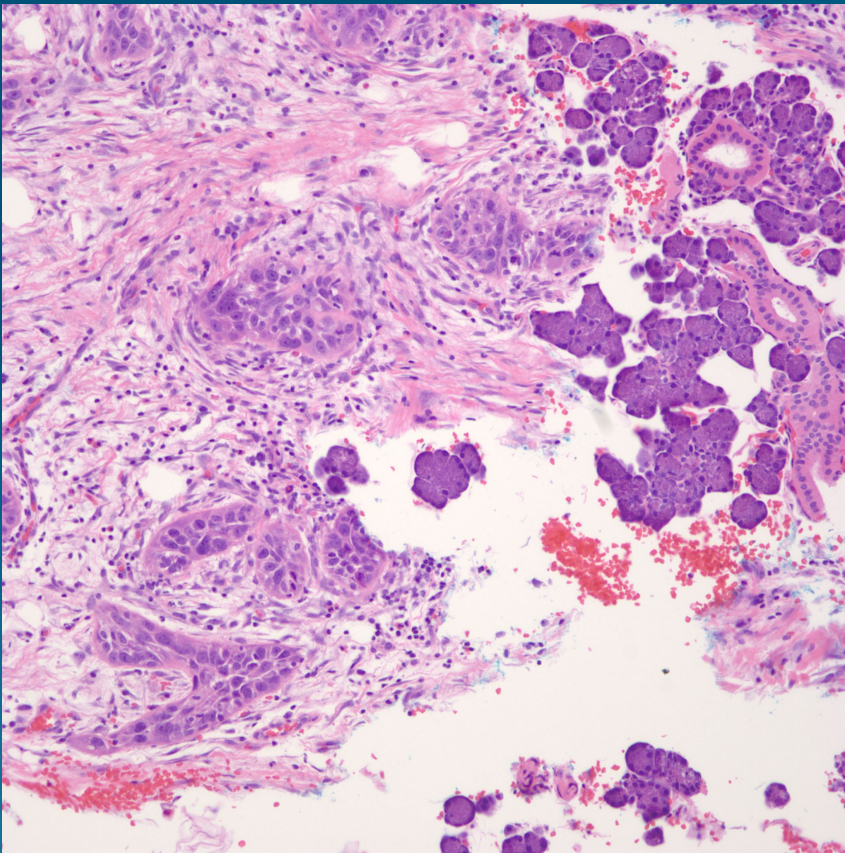
- A. Micronodular basal cell carcinoma
- B. Collision tumor basal cell carcinoma and squamous cell carcinoma
- C. Squamous cell carcinoma with salivary gland invasion
- D. Hidradenocarcinoma
- E. Merkel cell carcinoma



Squamous cell carcinoma with  
salivary gland invasion



# Pearls



- Conventional squamous cell carcinoma may invade into salivary gland tissue, depending upon location
- Note bland cytology and organoid arrangement of salivary gland tissue
- Rule out rare case of primary salivary gland squamous cell carcinoma